

DIABETIC FOOT ULCER DUE TO TRAUMA AFTER: A CASE REPORT

Achmad Fauji^{1*}, Uswatun Hasanah^{1,2}, Nur Miladiyah Rahmah¹, Puji Astuti¹, Rika Harini¹

¹Nursing Department, Faculty of Health and Pharmacy, Universitas Bani Saleh, Bekasi

²Nurse, Al-Faizin Wound Care Clinic, Bekasi

e-mail: achmad@ubs.ac.id; afauji.odji@gmail.com; achmad.fauji31@ui.ac.id

Artikel Diterima: 17 September 2025, Direvisi: 20 Februari 2026, Diterbitkan: 23 Februari 2026

ABSTRACT

Introduction: Diabetic foot ulcer due to trauma is serious complications that can lead to severe infections and even amputation, especially if treatment is delayed. **Purpose:** This case presentation to describe comprehensive wound management using evidence based and culturally adapted intervention in a traumatic diabetic ulcer. **Method:** A case report of a 40-year-old man who suffered a laceration on his left heel due to a traffic accident progressing to infected ulcer. Wound care was conducted using TIME CDST assessment, autolytic debridement, modern dressing with chitosan-zinc oxide ointment, and wound cleansing with boiled guava leaf (*Psidium guajava*) solution. The nursing diagnosis raised was impaired skin/tissue integrity. **Result:** Progressive wound healing was observed within two months, characterized by infection control, reduction of slough, increased granulation and epithelialization, and complete wound closure. **Discussion:** These findings suggest that combination of evidence-based wound care and culturally contextual herbal intervention demonstrated desirable outcomes. Early health education, structured monitoring, and documentation are crucial in preventing complications of chronic wounds in diabetic patients with trauma-related wounds.

Keywords: case report, diabetic foot, evidence-based nursing, wound care

INTRODUCTION

Diabetic ulcer due to trauma (DUDT) represents a notable clinical complication in diabetic patients, often resulting in severe consequences including infection, extended hospitalization, and lower extremity amputation. DUDT signifies traumatizing wounds that occur in individual with diabetes because of external injuries, including traffic accidents, puncture by sharp objects, or mechanical injuries that are exacerbated by underlying conditions like pre-existing neuropathy or peripheral arterial disease (PAD) (Suriadi, 2021, Singer et al., 2017). Unlike typical diabetic foot ulcers, DUDT can manifest in regions not usually subjected to pressure or callus development, differing from standard diabetic foot ulcers. These ulcers frequently display unusual healing responses attributable to vascular insuffi-

ciency and compromised immune function (Spiliopoulos et al., 2021, Forsythe et al., 2020).

Peripheral neuropathy, a common diabetic complication, reduces protective sensation in the extremities, allowing minor trauma to go unnoticed and untreated, thereby increasing the risk of chronic ulceration (Zhang et al., 2014, Shubhangi Vinayak, 2013). Contributing factors such as improperly fitting shoes, inadequate self-care, and insufficient awareness exacerbate this risk (Rosyid, 2017, Alexiadou and Doupis, 2012). Once ulceration occurs, infection often follows, leading to delayed healing, sepsis, and risk of amputation (Zhang et al., 2014, Haji Zaine et al., 2014). Other factors contribute to the exacerbation of this process, including the duration of diabetes, structural deformities, insufficient foot hygiene, and vascular

compromise (Zhang et al., 2014, Rosyid, 2017, Shubhangi Vinayak, 2013).

The management of DUDT requires comprehensive approach that includes wound cleansing, debridement, infection control through antibiotics, pressure offloading, and coordination among multiple disciplines (Shubhangi Vinayak, 2013, Alexiadou and Doupis, 2012, Haji Zaine et al., 2014, Zhang et al., 2014). Preventive strategies focus patient education, glycaemic control, regular foot inspections, and appropriate footwear (Rosyid, 2017, Alexiadou and Doupis, 2012).

The urgency of documenting a case report on DUDT stems from the clinical rarity and limited representation of traumatic diabetic ulcers in the literature.

Most existing evidence centres around neuropathic or ischemic diabetic foot ulcers, whereas DUDT—particularly those resulting from delayed or neglected post-trauma care—remain underreported. This knowledge gap affects clinical decision-making, especially in primary care and emergency settings where initial trauma management often overlooks long-term wound implications in diabetic patients. Theoretical guidance from Frykberg and Banks (2015) emphasizes that atypical diabetic ulcers require individualized assessment beyond standard DFU algorithms, particularly when trauma initiates ulcer formation without classic ischemic or neuropathic signs.

Research has thoroughly documented diabetic foot ulcers, however trauma-induced ulcers remain underreported, especially in the Indonesian clinical context. Limited reporting of integrative wound care, which blend evidence-based modern dressing with culturally appropriate traditional wound cleansing method, contribute to a lack of a standard practice in basic wound care setting. This case provides empirical information on adaptive nursing approaches for diabetic ulcers caused by trauma.

In this report, we present the case of a 40-year-old male with a history of uncontrolled diabetes who sustained a traumatic heel laceration following a motorcycle accident. Despite initial suturing, the wound progressed into a chronic ulcer due to irregular follow-up and inappropriate self-care. The wound exhibited purulent exudate, oedema, erythema, pain (NRS 7), and signs of infection. The case highlights the critical importance of early intervention, proper education, and consistent wound care follow-up in diabetic trauma patients.

METHOD STUDY DESIGN

This case report is prepared in accordance with the CARE guidelines (Gagnier et al., 2013) to ensure comprehensive and transparent reporting.

CASE PRESENTATION

A 40-year-old male patient, employed as a private sector worker, presented to the healthcare service with complaints of a foul-smelling wound on the left heel accompanied by sharp, stabbing pain rated at 7 out of 10, particularly when walking. The patient's medical history indicates that he was diagnosed with diabetes mellitus in 2020, with a random blood sugar level (RBS) of 380 mg/dL. Despite receiving metformin therapy at a dose of 2x500 mg per day, the patient admitted to not adhering to the medication regimen regularly.

In October 2023, the patient suffered a wound on the left heel due to shoes that were too tight. The wound healed after three months of treatment. However, on January 4, 2024, the patient was involved in a traffic accident that resulted in a laceration on the left heel. The wound was sutured by a doctor, and the patient was scheduled for a wound follow-up on January 7, 2024, but did not attend due to work commitments. Since then, the patient self-managed the wound without medical supervision until returning on January 11, 2024, with the wound having worsened.

CLINICAL FINDINGS

Physical examination on January 11, 2024, showed a wound measuring 7.1 x 3.8 cm, with 30% redness, 55% pink colour, and 15% yellowish slough. The wound was palpably swollen, warm, moist, and exuding yellowish-green purulent exudate. Assessment using the TIME CDST scale indicated 60% granulation, 25% slough, 5% necrosis, and 10% epithelialization. Signs of local infection were evident. Laboratory findings included: Haemoglobin (Hb) 13.7 g/dL, leukocytes 11,400/mm³, platelets 210,000/mm³, and GDS 360 mg/dL.

THERAPEUTIC INTERVENTION

Patient was given antibiotic therapy (Cefixime 2x200 mg), analgesics (Mefenamic Acid 3x500 mg), and a gastric protector (Omeprazole 1x20 mg), as well as wound care consisting of autolytic debridement, wound irrigation with 0.9% NaCl, and the use of a wound ointment containing chitosan-zinc oxide and foam dressing.

Starting January 18, 2024, an additional intervention was carried out in the form of wound washing using boiled guava leaves (*Psidium guajava*), which were boiled from 20 leaves in 1 litre of water until only 750 cc remained. This intervention was maintained until the wound was declared healed on March 10, 2024.

NURSING DIAGNOSIS AND INTERVENTION

Nursing diagnosis, nursing outcome, and nursing intervention are based on Indonesian Nursing Diagnosis Standard (SDKI), Indonesian Nursing Outcome Standard (SLKI), and Indonesia Nursing Interventions Standard (SIKI) (Fadhillah and Persatuan Perawat Nasional, 2018, Fadhillah and Persatuan Perawat Nasional, 2019, Fadhillah and Persatuan Perawat Nasional, 2017). The nursing diagnosis established is Skin/Tissue Integrity Disorder (D.0192) with the outcome criteria of

Skin and Tissue Integrity (L.14125), and the main intervention is Wound Care (I.14564). Interventions include wound cleaning, monitoring for signs of infection, administration of modern topical treatments, and monitoring of tissue development using the TIME CDST approach (Moore et al., 2019). Educational interventions such as introducing infection signs and self-care have not been optimally implemented.

There are several interventions in SIKI that have not been implemented, such as periodic repositioning, specific education, vitamin supplementation, and Transcutaneous Electrical Nerve Stimulation (TENS). Repositioning is not performed because the patient is still independent in mobilization. TENS is not given because pain is controlled with oral analgesics. Supplementation is not prescribed because oral intake is still sufficient.

JUSTIFICATION FOR EVIDENCE-BASED NURSING






The use of guava leaf boiled water as a wound-cleansing liquid is supported by recent studies showing the effectiveness of guava leaf extract in reducing bacteria that cause wound infections (especially *Staphylococcus aureus* and *Pseudomonas aeruginosa*) and accelerating tissue granulation (Jayakumari et al. (2023), (Bilal et al., 2024). This study used an experimental design with strong internal validity, adequate reliability of measurement tools, and high applicability in clinical wound nursing practice (JBI appraisal score >85%).


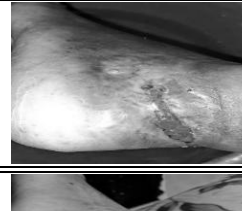

In addition, the use of wound ointments containing chitosan and zinc oxide refers to scientific evidence stating that this combination accelerates epithelialization, enhances angiogenesis, and has antimicrobial properties (Shu et al., 2023, Nabil et al., 2025). Chitosan provides haemostatic and tissue matrix formation effects, while zinc oxide accelerates epidermal regeneration (Adel Alawadi et al., 2024).

RESULTS

On January 11, 2024, the wound presented with purulent exudate and 25% slough. On January 25, 2024, blood glucose decreased to 220 mg/dl and granulation tissue increased. On February 8, 2024, epithelization progressed and inflammation decreased. On February 29, 2024, no signs of infection were observed and exudate was minimal. On March 10, 2024, complete epithelization was achieved without pain or malodour. Table 1. Shows the formation of wounds and the progression of wound follow-up.

Table 1. Wound Development (Follow-Up Timeline)

Time-line	Wound Description	Wound Images
04-Jan-2024	Post-accident laceration	
11-Jan-2024	Infected wound, purulent exudate, slough 25%, granulation 60%	
18-Jan-2024	Start using a guava leaf concoction, and the pain and odour will decrease.	
25-Jan-2024	Blood sugar levels dropped to 220 mg/dL, wound improvement began to be seen, and inflammation decreased.	
08-Feb-2024	The blood sugar level is 210 mg/dL, and there has	

Time-line	Wound Description	Wound Images
	been an increase in granulation and epithelization.	
29-Feb-2024	No signs of infection, minimal exudate.	
10-Mar-2024	The wound is healing well, with no pain, infection, or malodour.	

DISCUSSION

Diabetic ulcer due to trauma (DUDT) is a complication that develops from minor injuries in patients with poor glycaemic control. In this case, post-traumatic injury from a traffic accident, combined with severe hyperglycaemia (blood glucose level 380 mg/dL) and delayed treatment, triggered the development of a chronic infected wound. Clinical manifestations such as purulent exudate, severe pain, erythema, and slough indicate active infection, consistent with the criteria for diabetic wound infection (Frykberg and Banks, 2015). This case emphasizes that even minor trauma can develop into chronic ulcers in diabetic individuals with unstable metabolism.

The main strength of wound management lies in the adoption of evidence-based interventions, namely the use of boiled guava leaves (*Psidium guajava*) as a wound-cleansing fluid. This intervention is supported by the results of a study by Fauji et al. (2018), this substance exhibits antibacterial and anti-inflammatory properties, as well as the ability to reduce slough. This intervention was combined with the use of a wound ointment containing chitosan and zinc oxide, which synergistically enhanced granulation and epithelization.

lialization and accelerated the wound healing process (Sukmawati et al., 2022).

However, there are limitations in the implementation of nursing interventions according to the Indonesian Nursing Intervention Standards. Several aspects, such as patient education, vitamin supplementation, and the use of TENS, were not carried out or recorded. Education about signs of infection and wound care should be an integral part of management to prevent similar incidents. Vitamin supplementation was overlooked due to the assumption of adequate oral nutrition, despite the absence of formal nutritional assessments such as the Mini Nutritional Assessment (MNA) (Vellas et al., 1999). TENS was not used because the patient was already receiving systemic analgesics, but non-pharmacological intervention options should still be explored.

Autolytic debridement is the appropriate approach for this case, given the severe pain and minimal necrotic tissue (Mancini et al., 2018, Nuutila and Eriksson, 2021, Dayya et al., 2022). This therapy provides good results and maintains patient comfort, in line with the principles of patient-centred care. The use of foam dressings and modern ointments that accelerate epithelialization demonstrates the success of non-invasive conservative intervention.

The TIME CDST approach to wound assessment has proven to be a standardized, systematic framework that supports accurate clinical decision-making (Moore et al., 2019). Periodic evaluation of granulation, slough, infection, moisture, and wound edges facilitates monitoring of healing progress. However, incomplete clinical documentation, especially in education, needs to be improved as part of improving the quality of nursing services.

This case underlines the importance of evidence-based clinical adaptation that considers the local context and available resources. Nursing practice requires not only clinical competence, but also sensitivity to culture, economic cir-

cumstances, and patient behaviour. In accordance with the reflection model Rolfe et al. (2001)—“What? So what? Now what?”— This case serves as a lesson that delayed treatment, lack of education, and poor glycaemic control can prolong wound healing, thereby necessitating more active and structured interdisciplinary intervention.

PATIENT PERSPECTIVE

The patient stated that he chose to treat his wound independently at home due to work commitments and felt capable of caring for himself. However, this independent treatment caused the condition of the wound to worsen, accompanied by an unpleasant odour and increasing pain, resulting in significant discomfort. After starting regular wound care by a wound care nurse since January 11, 2024, the patient felt more comfortable, experienced reduced pain, and gradually resumed daily activities. The patient noticed positive changes from the fourth visit onward, with the wound finally healing completely by the 19th. The patient and their family expressed gratitude and satisfaction with the treatment outcomes, which not only successfully saved the limb from the risk of amputation but also restored the patient's overall quality of life.

CONCLUSION

This case describes a 40-year-old male patient with diabetes mellitus who suffered a diabetic ulcer due to trauma (DUDT) following a traffic accident. The uniqueness of this case lies in the delayed wound care due to ineffective self-management, as well as the successful wound healing achieved through evidence-based interventions combining modern wound dressings with herbal solutions (boiled guava leaves) and topical chitosan-zinc oxide ointment. The consistent use of the TIME CDST approach, along with regular monitoring and non-invasive therapy, demonstrated effectiveness in accelerating the healing of chronic wounds that

were initially at high risk of amputation complications. This case emphasizes the importance of early intervention, patient education, and the application of context-based reflective nursing practices in improving clinical outcomes for patients with traumatic diabetic wounds.

INFORMED CONSENT

Informed consent was obtained verbally and in writing from patients for each wound care procedure performed from January 11 to March 10, 2024. Before the procedure was performed, patients were provided with a comprehensive explanation of the procedure to be performed, its potential risks and benefits, as well as education on signs of infection and estimated wound healing time. The educational process was repeated to ensure patient understanding and active involvement in decision-making regarding their wound care.

ACKNOWLEDGEMENT

The authors acknowledge the clinical team involved in wound management and documentation through the treatment period.

AUTHOR CONTRIBUTION

Wound care was performed directly on patients by Author 1, Author 2, and Author 3. Author 4 and Author 5 played an active role in documenting the intervention and managing the clinical records required during the treatment process. The article was written by Author 1 and Authors 3–5, with consultation from Author 2 as the primary nurse practitioner, particularly in ensuring the completeness of data and the accuracy of the clinical documentation reported.

REFERENCES

Adel Alawadi, H., Andarzbakhsh, K., Rastegari, A., Mohammadi, Z., Aghsami, M. & Saadatpour, F. 2024. Chitosan-Aloe Vera Composition Loaded With Zinc Oxide

Nanoparticles For Wound Healing: In Vitro And In Vivo Evaluations. *IET Nanobiotechnol*, 2024, 6024411.

Alexiadou, K. & Doupis, J. 2012. Management of diabetic foot ulcers. *Diabetes Ther*, 3, 4.

Bilal, K., Mehboob, F., Akhtar, N., Mirza, I. A., Okla, M. K., Dar, M. J., Saleh, I. A., Zomot, N. & Fatima, H. 2024. Wound healing, antioxidant and antibacterial activities of polyphenols of *Psidium guajava* L. leaves. *South African Journal of Botany*, 165, 538-551.

Dayya, D., O'Neill, O. J., Huedo-Medina, T. B., Habib, N., Moore, J. & Iyer, K. 2022. Debridement of Diabetic Foot Ulcers. *Adv Wound Care (New Rochelle)*, 11, 666-686.

Fadhillah, H. & Persatuan Perawat Nasional, I. 2017. *Standar diagnosis keperawatan Indonesia: definisi dan indikator diagnostik*, Jagakarsa, Jakarta, Persatuan Perawat Nasional Indonesia.

Fadhillah, H. & Persatuan Perawat Nasional, I. 2018. *Standar intervensi keperawatan Indonesia: definisi dan tindakan keperawatan*, Jagakarsa, Jakarta, Persatuan Perawat Nasional Indonesia.

Fadhillah, H. & Persatuan Perawat Nasional, I. 2019. *Standar luaran keperawatan Indonesia: definisi dan kriteria hasil keperawatan*, Jagakarsa, Jakarta, Persatuan Perawat Nasional Indonesia.

Fauji, A., Sarwati, P., Rahmah, N. M. & Nirwana, A. S. 2018. Comparative study of effectiveness of wound cleansing solution in diabetic wound care. *Indonesian nursing journal of education and clinic (in-jec)*, 2, 37-41.

Forsythe, R. O., Apelqvist, J., Boyko, E. J., Fitridge, R., Hong, J. P., Katsanos, K., Mills, J. L., Nikol, S., Reekers, J., Venermo, M., Zierler, R. E., Schaper, N. C. & Hinchliffe, R. J. 2020. Performance

- of prognostic markers in the prediction of wound healing or amputation among patients with foot ulcers in diabetes: A systematic review. *Diabetes Metab Res Rev*, 36 Suppl 1, e3278.
- Frykberg, R. G. & Banks, J. 2015. Challenges in the Treatment of Chronic Wounds. *Adv Wound Care (New Rochelle)*, 4, 560-582.
- Gagnier, J. J., Kienle, G., Altman, D. G., Moher, D., Sox, H. & Riley, D. 2013. The CARE Guidelines: Consensus-based Clinical Case Reporting Guideline Development. *Glob Adv Health Med*, 2, 38-43.
- Haji Zaine, N., Burns, J., Vicaretti, M., Fletcher, J. P., Begg, L. & Hitos, K. 2014. Characteristics of diabetic foot ulcers in Western Sydney, Australia. *J Foot Ankle Res*, 7, 39.
- Jayakumari, S., Vijayalakshmi, A., Anandhi, N., Mounisha, B., Sameer, M. H. M. & Yogeshwaran, V. 2023. Wound healing and cytotoxic effects of tannin rich fraction of *Psidium guajava* L. leaves. *Annals of Phytomedicine An International Journal*, 12.
- Mancini, S., Cuomo, R., Poggialini, M., D'aniello, C. & Botta, G. 2018. Autolytic debridement and management of bacterial load with an occlusive hydroactive dressing impregnated with polyhexamethylene biguanide. *Acta Biomed*, 88, 409-413.
- Moore, Z., Dowsett, C., Smith, G., Atkin, L., Bain, M., Lahmann, N. A., Schultz, G. S., Swanson, T., Vowden, P., Weir, D., Zmuda, A. & Jaimes, H. 2019. TIME CDST: an updated tool to address the current challenges in wound care. *Journal of wound care*, 28, 154-161.
- Nabil, Y., Atta, A. H., El-Fattah, W. A., Hafez, H. S. & Elshaarawy, R. F. M. 2025. Progress in chitosan/essential oil/ZnO nanobiocomposites fabrication for wound healing applications: A review. *International Journal of Biological Macromolecules*, 318, 145123.
- Nuutila, K. & Eriksson, E. 2021. Moist Wound Healing with Commonly Available Dressings. *Adv Wound Care (New Rochelle)*, 10, 685-698.
- Rolfe, G., Freshwater, D. & Jasper, M. 2001. Critical reflection for nursing and the helping professions: a user's guide. Basingstoke: Palgrave.
- Rosyid, F. N. 2017. Etiology, pathophysiology, diagnosis and management of diabetics' foot ulcer. *International Journal of Research in Medical Sciences*, 5, 4206.
- Shu, G., Xu, D., Xie, S., Chang, L.-J., Liu, X., Yang, J., Li, Y. & Wang, X. 2023. The antioxidant, antibacterial, and infected wound healing effects of ZnO quantum dots-chitosan biocomposite. *Applied Surface Science*, 611, 155727.
- Shubhangi Vinayak, A. 2013. Chronic Leg Ulcers: Epidemiology, Aetiopathogenesis, and Management. *Ulcers*, 2013.
- Singer, A. J., Tassiopoulos, A. & Kirsner, R. S. 2017. Evaluation and Management of Lower-Extremity Ulcers. *N Engl J Med*, 377, 1559-1567.
- Spiliopoulos, S., Festas, G., Paraskevopoulos, I., Mariappan, M. & Brountzos, E. 2021. Overcoming ischemia in the diabetic foot: Minimally invasive treatment options. *World J Diabetes*, 12, 2011-2026.
- Sukmawati, P. F., Hidayat, R. & Naziyah, N. 2022. Analisis Asuhan Keperawatan Luka Kaki Diabetik pada Tn. I dan Ny. A dengan Penggunaan Zinc Cream dan Chitosan sebagai Balutan Primer di Wocare Center Bogor. *Jurnal Kreativitas Pengabdian Kepada Masyarakat (Pkm)*, 5, 4034-4045.
- Suriadi. An Appearance Characteristic Ulcer in Diabetic Patients at Kitamura Clinic in Pontianak, Indonesia. 2021.

Vellas, B., Guigoz, Y., Garry, P. J., Nourhashemi, F., Bennahum, D., Lauque, S. & Albarede, J. L. 1999. The Mini Nutritional Assessment (MNA) and its use in grading the nutritional state of elderly patients. *Nutrition*, 15, 116-22.

Zhang, J., Guan, M., Xie, C., Luo, X., Zhang, Q. & Xue, Y. 2014. In-

creased growth factors play a role in wound healing promoted by noninvasive oxygen-ozone therapy in diabetic patients with foot ulcers. *Oxid Med Cell Longev*, 2014, 273475.